

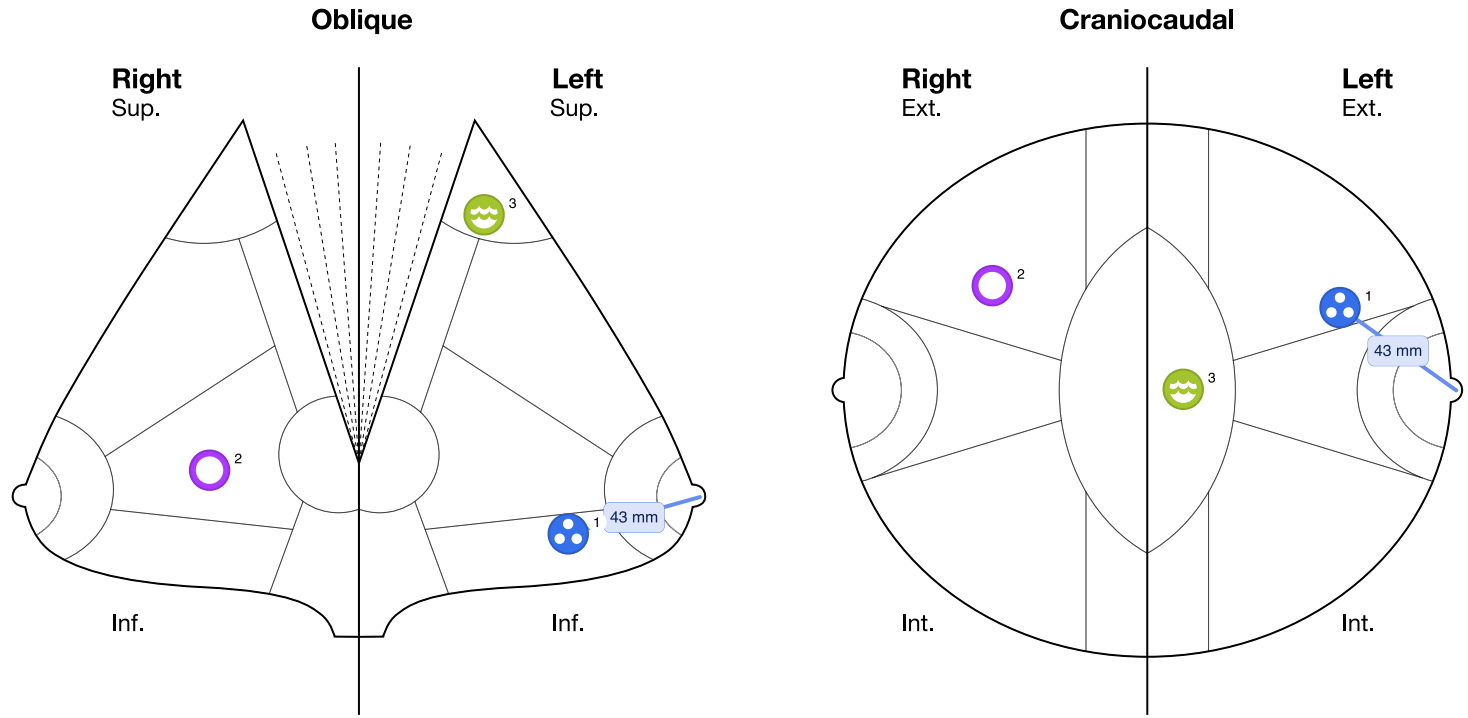
BIRADIX (17 MAY 1953)



Report date 12 Sep 2013
 Accession Number A10012399780
 Patient ID 12345
 Referring Physician Joris Heuberger

Observations

Density: ACR2 - Scattered areas of fibroglandular density



Type	Size	Distance	Characterization	Comment
1	1.1 mm	43 mm	Post-Op	
2			Undetermined	
3			Benign	

Conclusion

There's no significant abnormality to report. The breasts look the same (they are symmetrical) with no suspicious masses (lumps), distorted structures, or suspicious calcifications. There's no sign of cancer.

BI-RADS 2 - Benign finding(s)

Following Procedure: None