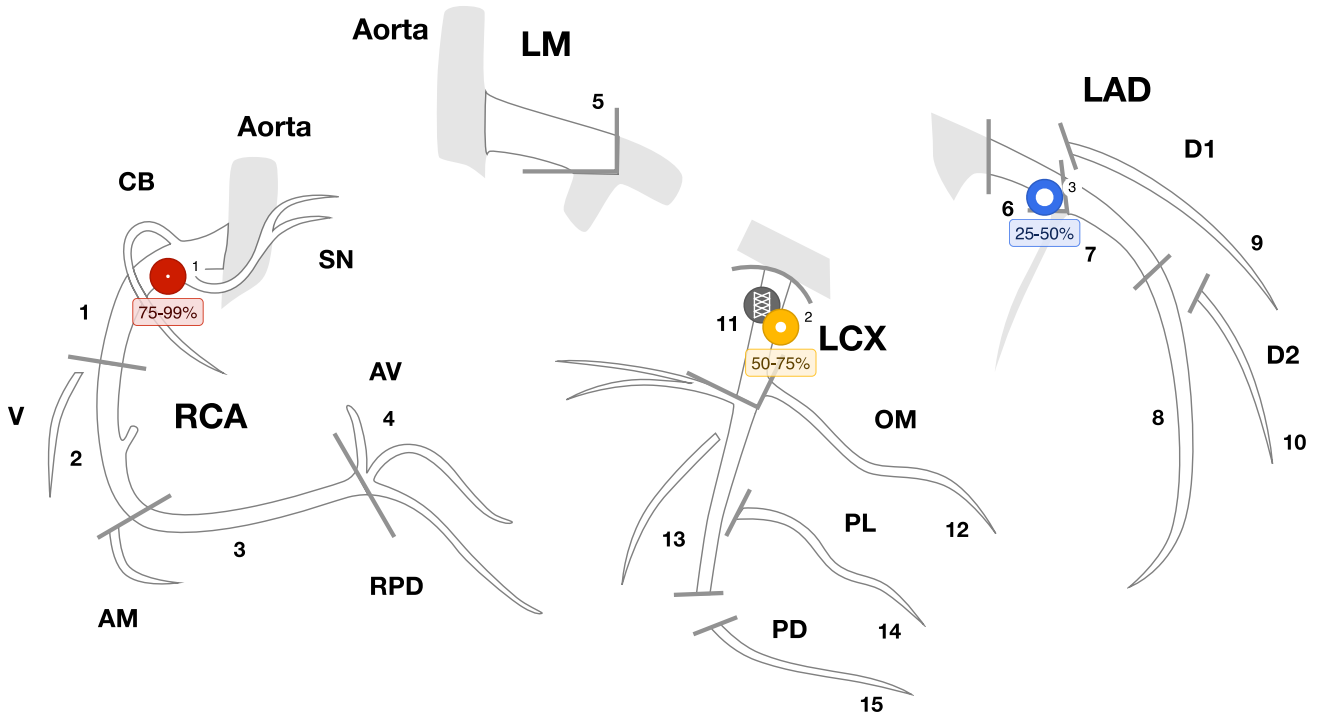


PELVIX (01 MAR 1967)

Report date 21 Sep 2015
 Accession Number 0
 Patient ID Vafm7b0J
 Referring Physician Joris Heuberger

Observations



Stent

Lesion	Segment	Type	Stenosis	Length
1	1	Undetermined	● 75-99%	1 mm
2	11	Mixed	● 50-75%	—
3	6	Calcified	● 25-50%	2.1 mm

Conclusion

Lorem ipsum dolor sit amet, case quas euismod id duo, no quo eligendi contentiones. Option commodo eligendi vim no, in has melius omnesque tacimates. Eu putant explicari has. Est ad referrentur theophrastus.

Ex suscipit perpetua contentiones per, no mel lorem dictas fastidii, assum iudicabit mei cu. Vivendum vulputate vel no. Ea equidem accusata iracundia nam, in has possim equidem periculis, animal commodo vel et. Per at quando dissentiet, quis erant verear te eos.

Per mutat errem platonem eu, diceret ceteros propriae eum ea. Ut diam docendi has, no prima fabulas omittantur vim, est cibo minimum insolens eu. Quas elitr laboramus pri ei, at omnium perpetua sed, ius id atqui labores. An vitae dissentiet eam.