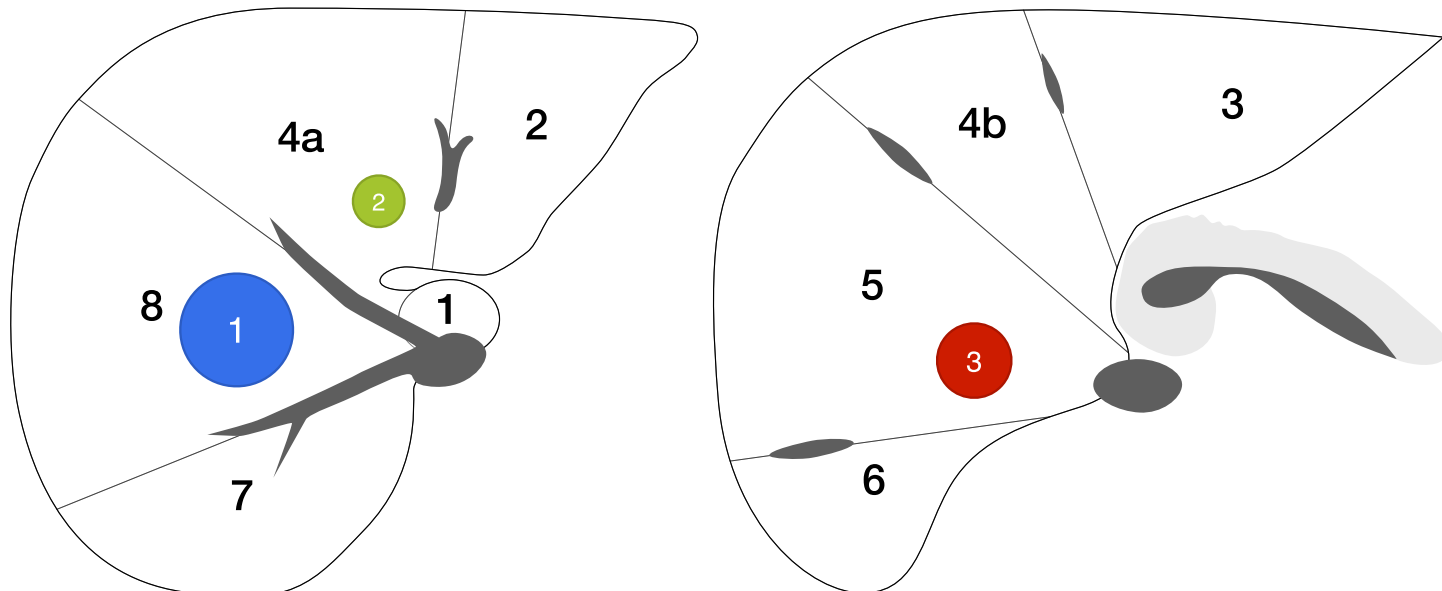


FIVIX

Report date 21 Sep 2015
 Patient ID FOYKBU

Observations



	Size	Characteristics	Diagnostic
1	4.5 mm	Calcification, Cyst, Fat, High T1	● Indeterminate
2	—	Calcification	● Benign
3	1.4 mm	Fat	● Certainly Malignant Lorem ipsum dolor sit amet

Conclusion

Lorem ipsum dolor sit amet, ne eam odio everti antiopam, quo hinc urbanitas id. Qui an audiam suscipit perfecto, nihil tantas reformidans ad eum. Ne mea sumo dolorum, est te aeterno similique elaboraret, has causae impedit iracundia no. Has ea ubique intellegam, nec laboramus hendrerit referrentur eu. Elitr ridens tractatos ex sed, has te lorem facilisis, eam an melius integre deserunt.

Has modus oportere expetendis ad. Putant explicari interesset at pri. Cum audiam eruditi detracto id, voluptaria reprimique mea ex, nam agam duis ipsum id. Mel magna legere libris an. Probo velit dignissim vis ut, ius dolorem occurreret dissentiet ea, id ius atqui imperdiet.